

<Case Report>

Multidisciplinary Treatment Comprising Heavy Particle Radiotherapy and Hyperthermia is Effective Against Liver Metastasis Arising from Pancreatic Cancer: A Case Report

Tetsunosuke SHIMIZU¹, Kohei TANIGUCHI², Mitsuhiro ASAKUMA¹,
Atsushi TOMIOKA¹, Shuji KAGOTA¹, Koji KOMEDA¹, Sang-Woong LEE¹,
Fumitoshi HIROKAWA¹, and Kazuhisa UCHIYAMA¹

*1 Department of General and Gastroenterological Surgery, Division of Surgery,
Faculty of Medicine, Osaka Medical and Pharmaceutical University,
Takatsuki, Osaka 569–8686, Japan*

*2 Translational Research Program, Osaka Medical and Pharmaceutical University,
Takatsuki, Osaka 569–8686, Japan*

Key words: Heavy ion therapy, Heavy particle radiotherapy, Hyperthermia,
Pancreatic cancer, Radiotherapy

ABSTRACT

Pancreatic cancer is a leading cause of cancer-related deaths. Although advances in chemotherapy and radiotherapy have improved patient outcomes, pancreatic cancer remains a refractory disease. Herein, we describe a patient with pancreatic cancer who underwent an effective multidisciplinary treatment comprising heavy particle radiotherapy and hyperthermia. A 64-year-old woman underwent distal pancreatectomy for pancreatic cancer; however, a single liver metastasis was discovered 12 months after surgery. Heavy particle radiotherapy and oral tegafur/gimeracil/oteracil were administered to treat the metastasis. Thereafter, the patient underwent laparoscopic lateral segmentectomy of the liver. However, 12 months after hepatectomy, peritoneal dissemination with elevated serum carbohydrate antigen 19-9 levels was detected. The patient received combination therapy with gemcitabine and nanoparticle albumin-bound paclitaxel and subsequently underwent hyperthermia therapy with low-dose S-1 administration. While serum carbohydrate antigen 19-9 levels decreased more than expected over the first 9 months of hyperthermia therapy, the patient died the following month. Overall, the patient survived for 4 years after liver metastasis was detected and 3 years post-peritoneal dissemination. In an era where novel therapeutic strategies are required for treating aggressive malignancies, our report illustrates the potential effectiveness of multidisciplinary treatments in patients with unresectable pancreatic cancer.

Address correspondence to:

Tetsunosuke Shimizu, M.D., Ph.D., Department of General and Gastroenterological Surgery, Division of Surgery, Faculty of Medicine, Osaka Medical and Pharmaceutical University, 2–7 Daigakumachi, Takatsuki, Osaka 569–8686, Japan
Phone: +81–72–683–1221 Fax: +81–72–685–2057 E-mail: 0315shimizu@gmail.com

INTRODUCTION

Various chemotherapy, radiotherapy, and surgical treatments have been devised over the years for the treatment of recurrent pancreatic cancer. However, patient outcomes remain unsatisfactory to date, with liver metastasis and peritoneal dissemination frequently occurring, despite aggressive treatment. Effective treatment modalities for recurrent tumors are extremely rare. However, recently, heavy particle radiotherapy has been shown to be effective against many types of solid cancers, including lung, bone, soft-tissue, hepatocellular carcinoma, locally recurrent rectal cancer, and pancreatic cancer [1, 2]. Hyperthermia (HTM) is another treatment option for solid cancers and their metastases [3]. Herein, we report a patient with pancreatic cancer for whom multidisciplinary treatments for liver metastasis and subsequent peritoneal dissemination were remarkably effective.

CASE PRESENTATION

A 63-year-old woman was admitted to our hospital with left hypochondrial pain. After routine examinations, computed tomography (CT) revealed a tumor located in the pancre-

atic body (**Figure 1a**). The patient underwent distal pancreatectomy with lymph node dissection in April 2012. Pathological findings confirmed a diagnosis of well-differentiated adenocarcinoma (T3, N0, M0, stage IIA based on the General Rules for the Study of Pancreatic Cancer, seventh edition) (**Figure 1b**) [4]. The patient was discharged without any post-operative complications on day 14.

The patient was administered gemcitabine (GEM) intravenously (1,000 mg/m² on days 1, 8, and 15, every 28 days for 9 cycles) as adjuvant chemotherapy. Follow-up CT performed 11 months after commencing GEM revealed a metastatic lesion in the lateral segment of the liver (**Figure 1c**), following which oral S-1 therapy (100 mg/m²) was administered. After 3 cycles of S-1 therapy, heavy particle radiotherapy was introduced to target the liver metastasis (68 Gy total), at the patient's request, in November 2013. The size of the metastatic tumor in the liver remained unchanged for 6 months after commencing heavy particle radiotherapy (**Figure 1d**); as such, the metastasis was assessed as stable.

Surgical intervention was subsequently performed after confirming the absence of any other recurrences via fluorodeoxyglucose positron emission tomography. The metastatic liver tumor was resected via single-port laparoscopic surgery

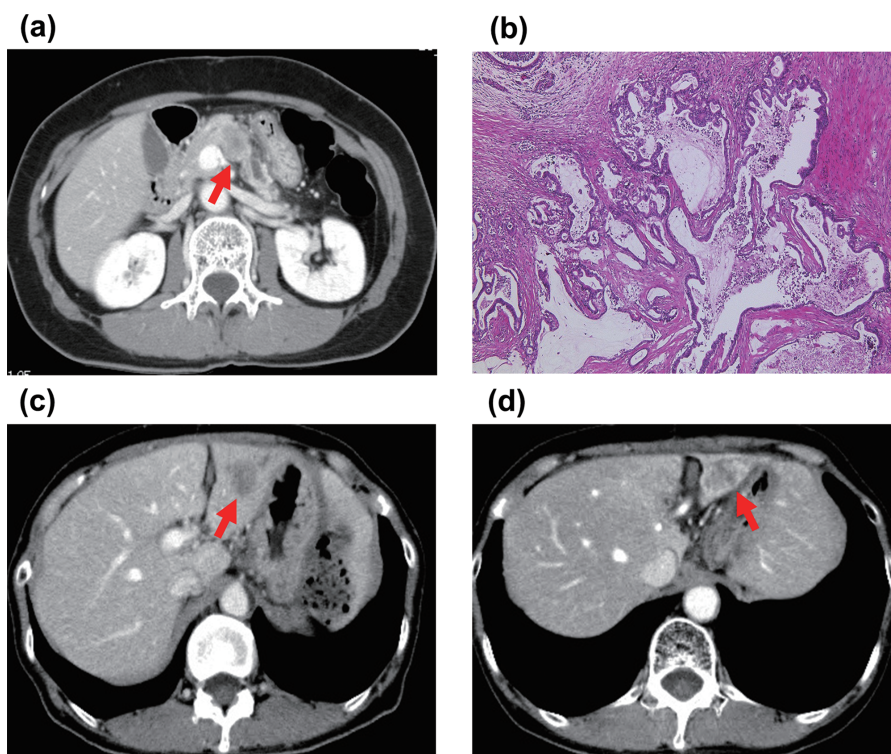


Figure 1 Tumor features at diagnosis and after initial treatment

(a) Contrast-enhanced computed tomography revealed a tumor in the pancreas (red arrow). (b) Hematoxylin and eosin staining of the specimen obtained by distal pancreatectomy showed a well-differentiated adenocarcinoma (magnification, $\times 4$). (c) Liver metastasis was observed in the lateral segment of the liver (red arrow). (d) The size of the metastatic liver tumor remained unchanged for 6 months following heavy particle radiotherapy (red arrow).

after the patient provided written informed consent in June 2014. Evaluation of the resected specimen using the Evans staging criteria revealed a grade IIa lesion (**Figure 2**). Additionally, immunohistochemical staining revealed that the tumor was positive for cytokeratin 7; carbohydrate antigen 19-9 (CA19-9); and mucin 1, cell surface-associated. The tumor was negative for cytokeratin 20 (**Figure 3a**). Identical results were observed in the removed liver tumor specimen (**Figure 3b**), confirming the liver lesion's pancreatic origin. The patient was discharged 10 days after hepatectomy with no complications.

However, 12 months later, peritoneal dissemination to the left kidney was observed (**Figure 4**), with elevated serum CA19-9 levels (165.4 U/ml). GEM plus nanoparticle albumin-bound paclitaxel was administered intravenously for 7 cycles (800 mg/m² and 100 mg/m², respectively, on days 1, 8, and 15, every 28 days). However, the solid peritoneal dissemination gradually increased as serum CA19-9 levels continued to rise (**Figure 5**). Based on these findings, HTM therapy was performed with oral administration of low-dose S-1 once every 10 days as systemic treatment. Consequently, serum CA19-9 levels gradually decreased over 9 months (**Figure 5**). However, peritoneal dissemination suddenly appeared in the stomach, and the patient died 10 months after commencing HTM therapy.

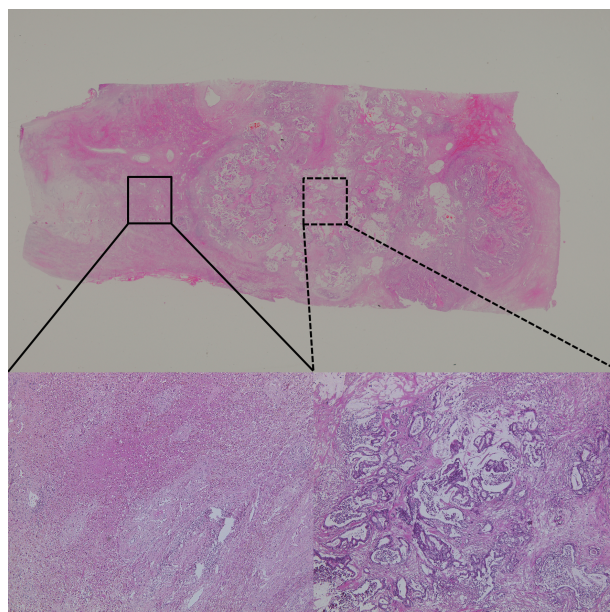


Figure 2 Evaluation of the resected specimen

Loupe image (upper panel) revealed that approximately 30 % of the tumor cells were destroyed (Evans criteria: IIa). The left lower panel (black box) shows the area of destruction, while the right lower panel (black dotted box) shows the area of residual cancer (magnification, $\times 4$).

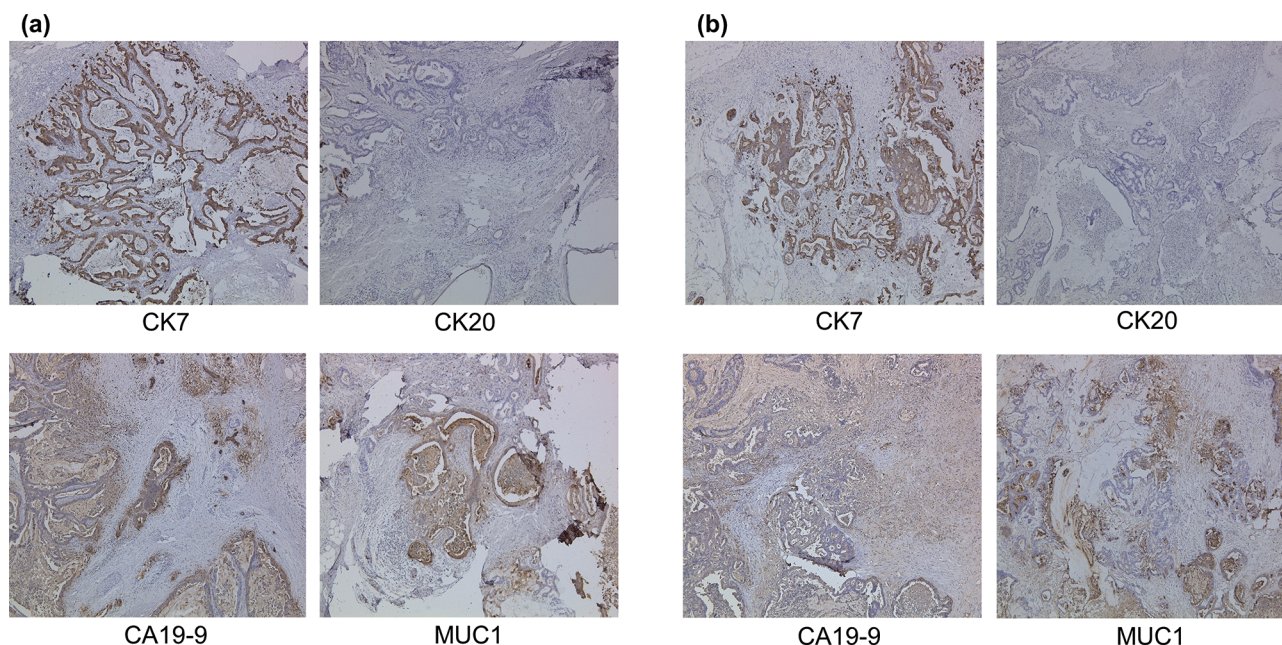


Figure 3 Immunohistochemical analyses of the resected specimen

(a) Immunohistochemistry of the excised pancreatic tumor showed positive staining for CK7, CA19-9, and MUC1, but negative staining for CK20 (magnification, $\times 4$). (b) Immunohistochemistry of the excised liver tumor showed positive staining for CK7, CA19-9, and MUC1, but negative staining for CK20 (magnification, $\times 4$). CA19-9, carbohydrate antigen 19-9; CK7, cytokeratin 7; CK20, cytokeratin 20; MUC1, mucin 1, cell surface-associated.

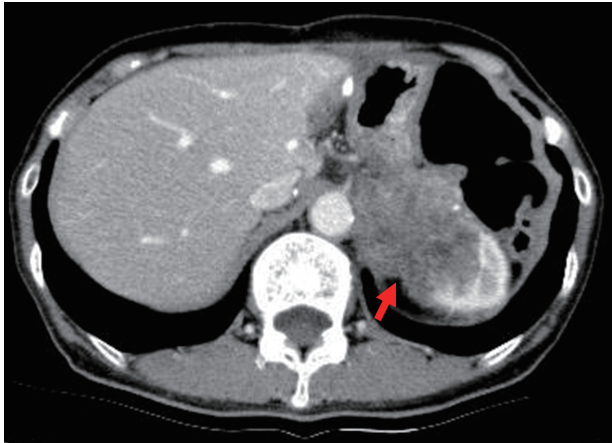


Figure 4 Computed tomography 12 months after liver metastatic tumor resection
Peritoneal dissemination to the left kidney was observed (red arrow).

DISCUSSION

The key interventions we highlight in this report are performing hepatectomy after heavy particle radiotherapy for liver metastasis and administering HTM therapy with low-dose S-1 for peritoneal dissemination.

Surgical intervention for pancreatic cancer recurrence remains controversial, despite the publication of several large-scale studies that evaluated the outcomes of patients who underwent such resections. For example, Klempnauer *et al.* [5] found that the median survival times for patients who underwent curative-intent resection of synchronous *versus* metachronous liver metastases were 8.3 and 5.8 months, respectively. Similarly, Takada *et al.* [6] found no significant difference in survival outcomes between patients who underwent hepatic resection with pancreaticoduodenectomy and those who underwent palliative bypass procedures. Based on their data, neither group viewed hepatic resection for pancreatic cancer liver metastasis favorably. However, our patient experienced longer survival after adding heavy particle radiotherapy to the treatment plan, in addition to hepatectomy.

Heavy particle radiotherapy with protons or carbon ions has recently been highlighted in cancer treatment [7]. This technology has the following advantages: 1) the increase in energy deposition with heavy particles is commensurate with depth, 2) heavy particles produce stronger biological effects than X-rays, and 3) tumors that are radioresistant to conventional X-ray radiotherapy may nevertheless be sensitive to heavy particle radiotherapy. Regarding the use of this technology for patients with clinical stage IVa and IVb pancreatic cancer without distant metastases, Okada *et al.* [1] reported that the 1-year overall local control and survival rates were 81 % and 44 %, respectively. Similarly, Kamada *et al.* [2]

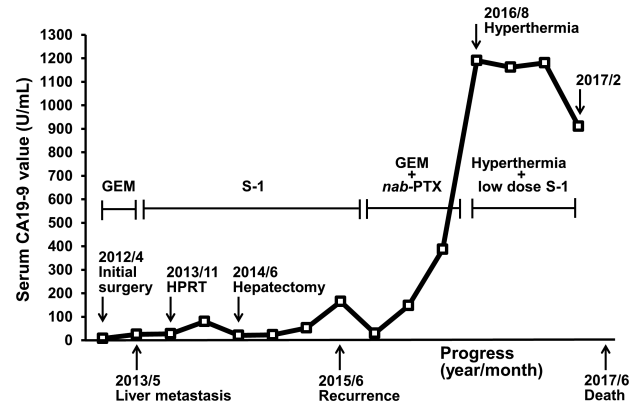


Figure 5 Time course of changes in serum CA19-9 levels
Changes in serum CA19-9 levels from the time of initial surgery to death are shown. CA19-9, carbohydrate antigen 19-9; GEM, gemcitabine; HPRT, heavy particle radiotherapy; *nab*-PTX, nanoparticle albumin-bound paclitaxel.

reported favorable outcomes for patients with locally advanced unresectable pancreatic tumors using this technology. The 2-year local control and overall survival rates in their study were 58 % and 54 %, respectively; the median survival time was twice as long as that when using the best standard treatment (i.e., conventional radiotherapy and GEM) [2]. These studies demonstrated the effectiveness of heavy particle radiotherapy for treating pancreatic cancer, but not recurrent lesions. Interestingly, histological analysis of our patient's resected liver revealed that the rate of tumor cell necrosis was only 20 % (Evans criteria: IIa) (Figure 2) [8]. As such, the ablative power of heavy particle radiotherapy against pancreatic cancer may be unexpectedly weak; however, high local control was achieved using this method, including the suppression of both tumor enlargement and spread to distant sites.

The goal of employing HTM in oncology is to kill tumor cells and enhance anti-tumor immunity by raising the body temperature either locally or systemically [9, 10]. Additionally, the higher temperatures (39–41 °C) damage not only normal tissues but also activate anti-tumor immune responses. In terms of the latter, Ito *et al.* [11] reported that tumor cells heated *in vitro* to 43 °C for 30 min had increased levels of surface major histocompatibility complex class I, which allowed for better recognition by CD8-positive T cells. The enhanced lysis of tumor cells by CD8-positive T cells and natural killer cells may further improve anti-tumor immune responses [11]. Moreover, increased cell membrane permeability and inhibition of DNA damage repair are considered the primary mechanisms of a synergistic effect of HTM therapy and chemotherapy [12].

In our patient, dissemination was localized to the left kidney, and HTM therapy was performed with oral administra-

tion of low-dose S-1 once every 10 days. Although it is a systemic treatment, we used HTM therapy to target a localized lesion. Further studies are required to establish a standard therapeutic strategy. However, we recommend combination therapy as first- or second-line chemotherapy.

Of particular note was our patient's improved symptoms, such as fatigue and anorexia. Furthermore, the patient remained in good condition without experiencing severe complications. Notably, the patient survived for 4 years following the detection of liver metastasis, and for 2 years following peritoneal dissemination. The development of additional novel therapeutic interventions may extend the survival of patients with similar conditions.

Hence, when we encounter a similar case, we proceed with heavy particle radiotherapy or HTM therapy, if the patient agrees. If the patient refuses heavy particle radiotherapy, we administer chemotherapy (GEM and abraxane). Then, in cases without distant metastasis, we perform surgical resection 6 months later.

In conclusion, our patient's disease course highlighted three potentially efficacious treatments for liver metastasis arising from pancreatic cancer: First, surgical resection of the metastatic liver lesion; second, heavy particle radiotherapy that was effective against the liver metastasis; and third, HTM therapy in combination with anticancer agents. Identifying such effective combination therapies is critical for improving the outcomes of patients with this disease in the future.

ACKNOWLEDGMENTS

The authors are grateful for the cooperation of all staff engaged in patient treatment. We would like to thank Editage (www.editage.com) for their writing support. Written informed consent was obtained from the patient for the publication of this case report while the patient was still alive, and the patient's identity was fully anonymized.

AUTHORS' CONTRIBUTIONS

T.S. and K.T. designed the concept of the report. T.S. drafted the manuscript. K.T. and S.-W.L. reviewed and revised the manuscript. T.S. and K.T. visualized the data. K.U. supervised the patient's treatment and the writing of the report. M.A., A.T., S.K., K.K., S.-W.L., F.H., and K.U. analyzed and interpreted data. All authors read and approved the final manuscript.

DISCLOSURE STATEMENT

The authors declare that they have no competing interests. This research did not receive any specific grant from funding agencies in the public, commercial, or not-for-profit sectors.

REFERENCES

- Okada T, Kamada T, Tsuji H, Mizoe JE, Baba M, Kato S, Yamada S, Sugahara S, Yasuda S, Yamamoto N, Imai R. Carbon ion radiotherapy: clinical experiences at National Institute of Radiological Science (NIRS). *J Radiat Res* 2010;51:355-64.
- Kamada T, Tsujii H, Blakely EA, Debus J, De Neve W, Durante M, Jäkel O, Mayer R, Orecchia R, Pötter R, Vattinsky S. Carbon ion radiotherapy in Japan: an assessment of 20 years of clinical experience. *Lancet Oncol* 2015; 16:e93-100.
- Wust P, Hildebrandt B, Sreenivasa G, Rau B, Gellermann J. Hyperthermia in combined treatment of cancer. *Lancet Oncol* 2002;3:487-97.
- Japan Pancreas Society. General Rules for the Study of Pancreatic Cancer, 7th ed. Tokyo, Japan: Kanehara & Co., Ltd., 2016. (in Japanese)
- Klempnauer J, Ridder GJ, Bektas H, Pichlmayr R. Extended resections of ductal pancreatic cancer--impact on operative risk and prognosis. *Oncology* 1996;53:47-53.
- Takada T, Yasuda H, Amano H, Yoshida M, Uchida T. Simultaneous hepatic resection with pancreato-duodenectomy for metastatic pancreatic head carcinoma: does it improve survival? *Hepatogastroenterology* 1997; 44:567-73.
- Ohno T. Particle radiotherapy with carbon ion beams. *EPMA J.* 2013;4:9.
- Evans DB, Rich TA, Byrd DR, Cleary KR, Connelly JH, Levin B, Charnsangavej C, Fenoglio CJ, Ames FC. Pre-operative chemoradiation and pancreaticoduodenectomy for adenocarcinoma of the pancreas. *Arch Surg* 1992;127: 1335-9.
- Hegyí G, Szigetí GP, Szász A. Hyperthermia versus oncothermia: cellular effects in complementary cancer therapy. *Evid Based Complement Alternat Med* 2013;2013: 672873.
- Garg AD, Galluzzi L, Apetoh L, Baert T, Birge RB, Bravo-San Pedro JM, Breckpot K, Brough D, Chaurio R, Cirone M, Coosemans A. Molecular and translational classifications of DAMPs in immunogenic cell death. *Front Immunol* 2015;6:588.
- Ito A, Tanaka K, Kondo K, Shinkai M, Honda H, Matsu-moto K, Saida T, Kobayashi T. Tumor regression by combined immunotherapy and hyperthermia using magnetic nanoparticles in an experimental subcutaneous murine melanoma. *Cancer Sci* 2003;94:308-13.
- Hirobumi O, Satoshi A, Tomoaki S, Hajime M, Morikazu A, Kaoru T, Tohru T, Takeo H. The Drug Uptake in the Tumor When the Mild-Hyperthermia Treatment in Combination with the Chemotherapy in vivo. *Thermal Medicine (JPN J. Hyperplastic Oncology)*. 2006;22:22-33.

Received October 20, 2020

Accepted May 14, 2021