

Diagnostic Imaging Study of the Relationship Between the Mandibular Third Molar and Mandibular Canal –Use of Helical Computed Tomography for Multiplanar Reconstruction–

| | |
|-------|--|
| メタデータ | 言語: English 出版者: 公開日: 2023-03-18 キーワード (Ja): キーワード (En): 作成者: SAKINAKA, Isao, SHIMAHARA, Masashi, ARIYOSHI, Yasunori メールアドレス: 所属: |
| URL | https://doi.org/10.57371/00000335 |

<Original Article>

Diagnostic Imaging Study of the Relationship Between the Mandibular Third Molar and Mandibular Canal -Use of Helical Computed Tomography for Multiplanar Reconstruction-

Isao SAKINAKA^{1,2}, Masashi SHIMAHARA² and Yasunori ARIYOSHI²

*1 Division of Dental Clinic, Aobaoka Hospital,
Osaka Sayama-city, Osaka 589-0004, Japan*

*2 Department of Dentistry and Oral Surgery, Division of Medicine for
Function and Morphology of Sensory Organs, Faculty of Medicine,
Osaka Medical College, Takatsuki-city, Osaka 569-8686, Japan*

Key words: mandibular third molar, mandibular canal, panoramic radiography,
helical computed tomography, multiplanar reconstruction images

ABSTRACT

We aimed to evaluate the ability of panoramic radiography to reflect the information provided by three-dimensional CT scans of the mandibular third molar and mandibular canal by comparing panoramic radiographs with CT scans. Panoramic radiography was used to evaluate the superimposition of the third molar root apex with the mandibular canal and deflection of the mandibular canal at the third molar root apex. Deflection and compression of the mandibular canal was detected by cine display of cross-sectional images. For each case, panoramic radiographs and Tooth-Pix images of the CT scans were compared. Results showed a higher incidence of mandibular canal deflection with an increase in overlap between the mandibular canal and third molar root apex. In the present study, a bone wall was absent more often in cases in which the mandibular canal traveled on the lingual side than in cases in which it traveled on the buccal side and above the tooth axis. Therefore, it may be necessary to carefully examine morphology as well as anatomic position when analyzing the mandibular canal image. It may be necessary to pay closer attention during tooth extraction when the root apex is below the lower mandibular canal wall, or when widening of the mandibular canal by a considerable portion of the third molar is observed on panoramic radiograph. Therefore, pre-surgical CT may be needed to determine the positional relationship when mandibular canal deflection at the root apex is detected by panoramic radiography.

Address correspondence to:

Masashi Shimahara, Department of Dentistry and Oral Surgery, Division of Medicine for Function and Morphology of Sensory Organs, Faculty of Medicine, Osaka Medical College, 2-7 Daigaku-machi, Takatsuki-city, Osaka 569-8686, Japan
Phone: +81-72-684-6438 Fax: +81-72-684-6538 E-mail: ora001@poh.osaka-med.ac.jp

INTRODUCTION

The third molar (wisdom tooth) is the last of the permanent teeth to erupt. However, insufficient space between the third molar and mandibular bone can prevent eruption or cause malposition. These conditions can result in inflammation or pericoronitis, which often necessitates third molar extraction. The relative positions of the third molar root apex and maxillary sinus must be taken into account during extraction of the maxillary third molar. Because the mandibular third molar root apex is often close to the mandibular canal, its extraction may damage the inferior alveolar neurovascular bundle, thereby causing residual chin and lower lip paresthesia. After mandibular third molar extraction, the incidence of permanent mental region and lower lip numbness after mandibular wisdom tooth extraction is 0.5% to 1%, and the incidence of temporary numbness is 5% to 7% [1,2]. Therefore, pre-surgical planning requires an understanding of the three-dimensional relationships between the maxillary third molar root apex and maxillary sinus and between the mandibular third molar root apex and mandibular canal.

To understand the relationship between the third molar and mandibular canal, panoramic radiography is typically performed to determine the inclination of the tooth axis and degree of impaction. In recent years, use of helical computed tomography and dental cone-beam computed tomography (helical CT and dental cone-beam CT) during common procedures such as implants and third molar extractions in dental and oral surgery clinical practices have improved visualization of the three-dimensional structure of the mandible [3-7]. However, CT scans cannot be performed for every impacted mandibular third molar extraction because of concerns about radiation exposure and high medical costs. Therefore, it may be necessary to determine whether accuracy of panoramic radiography can accurately assess the proximity of the third molar root apex and the mandibular canal.

In the present study, we aimed to evaluate the ability of panoramic radiography to reflect the information provided by three-dimensional CT scans of the mandibular third molar and mandibular canal by comparing panoramic radiographs with CT scans.

MATERIAL and METHOD

Panoramic radiography was performed at our hospital on 824 patients who underwent third molar extraction at Osaka Medical College Hospital, Department of Oral Surgery from January 1996 to December 2003. We were able to clearly visualize the third

molar root apex and mandibular canal in 141 of the 824 cases. Contact between the third molar root apex and the mandibular canal was observed in these cases; therefore, they were included in our study (Figure 1).

As shown in Table 1, the mean age of the 141 patients was 29.6 years (age range, 17-56 years; 17-19 years, n = 8; 20-29 years, n = 85; 30-39 years, n = 31; 40-49 years, n = 15; 50-59 years, n = 2). Of the 41 male and 100 female patients, 69 patients were examined on the right side and 72 patients were examined on the left side.

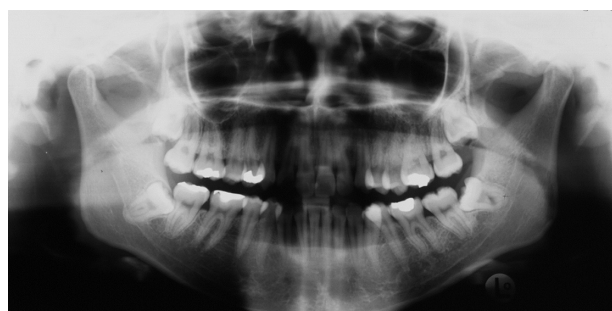

Figure 1 Panoramic radiograph

Table 1. Patient population.

| | |
|--------------|--------------------|
| Age | |
| Mean (range) | 29.6 yr (17-56 yr) |
| Sex, n | |
| Male | 41 |
| Female | 100 |

Panoramic radiographic analysis

Equipment and imaging conditions

PANEX panoramic radiographs (Morita Corporation) were used in this study. Images were obtained by angling the main shaft of the x-ray beam 10° above the occlusal plane.

Methods of analysis

Analysis of mandibular canal deflection, morphology and radiolucency of the third molar root apex, and position of third molar root apex relative to the mandibular canal

Panoramic radiography was used to evaluate the superimposition of the third molar root apex with the mandibular canal and deflection of the mandibular canal at the third molar root apex. The superimposition between third molar root apex and mandibular canal was assessed by tracing the third molar root and upper and lower walls of the mandibular canal,

through their positions relative to one another. Mandibular canal deflection was determined as the curvature of mandibular canal at the base of the third molar despite parallel appearance of the upper and lower walls. Morphology of the third molar root apex was determined by the presence or absence of root curvature. Third molar position was categorized as: Class I, third molar root apex in contact with the upper wall of the mandibular canal; Class II, third molar root apex positioned between the upper and lower walls; or Class III, third molar root apex positioned below the lower wall of the mandibular canal. In addition, a mandibular canal that was not curved at the third molar root apex was categorized as Class a, and a curved mandibular canal was categorized as Class b (Figure 2).

We analyzed the variation in translucency of the third molar root apex by comparing translucency of the root area that overlapped with the mandibular canal with translucency of the root area that did not overlap.

Analysis of mandibular canal radiolucency and morphologic changes of the mandibular canal at the point of contact with the third molar root apex

We analyzed structural changes of the mandibular canal, including thickening/interruption of the white line of the upper and lower mandibular canal walls, and narrowing/widening of the mandibular canal at the point of contact with the third molar. Narrowing/widening of the mandibular canal was determined by the degree in which the upper and lower mandibular canal walls ran parallel to one another (Figure 3).

Furthermore, we determined changes in radiolucency of the mandibular canal as the difference between translucency of the mandibular canal region adjacent to the third molar, and translucency of mesio-distal regions.

In cases in which multiple panoramic radiographic images of the third molar and mandibular canal existed for a patient, each image was considered a single finding and the total was listed.

Helical CT image analysis

Equipment and imaging conditions

An X-force/SE CT scanner (Toshiba Corporation, Tokyo, Japan) was used under the following conditions: x-ray beam, 1mm wide; table movement, 1 mm/sec; x-ray tube rotations, 1 rotation/sec during the 50-sec scan; 150 mA; 130 kVp. The line of reference was parallel to the inferior border of the mandible. Each slice was an axial CT image with a pitch of 0.5 mm; a 360° interpolation method was used to reconstruct the CT images.

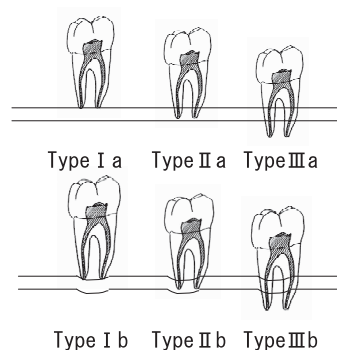


Figure 2 Schema of relation between third molar tooth and mandibular canal in panoramic radiography.

Panoramic radiography is used to evaluate the overlap of the third molar root apex with the mandibular canal. In addition, a mandibular canal that is not curved at the third molar root apex is categorized as Class a, and a curved mandibular canal is categorized as Class b.

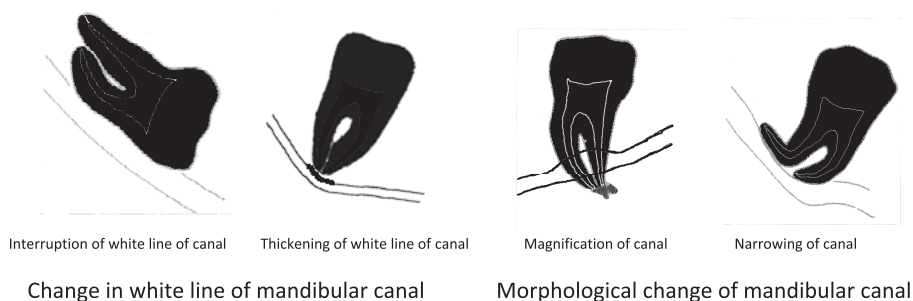


Figure 3 Schema of mandibular canal white line and morphological change.

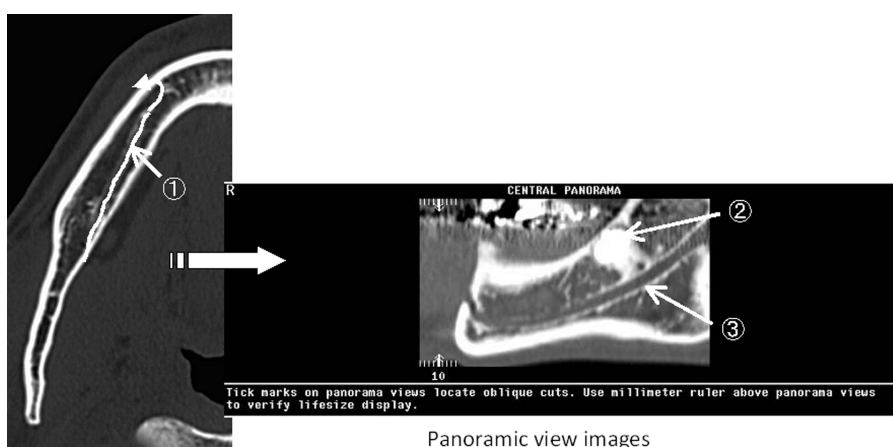
We analyzed structural changes of the mandibular canal, including thickening/interruption of the white line of the upper and lower mandibular canal walls, and narrowing/widening of the mandibular canal at the point of contact with the third molar.

A DICOM workstation with Sun SPARC 20(Sun Microsystems, Palo Alto, CA) hardware and X-tension (Toshiba Corporation) and Tooth-Pix™ software were used for image analysis.

Analytical methods

Volume data obtained by helical CT imaging was uploaded to the Sun SPARC 20 DICOM workstation. Series of axial images were selected and processed by Tooth-Pix™ software, and the images were analyzed with X-tension. We obtained cross-sectional (CS) and panoramic view (PV) images from these analyses, and used cine mode display for dynamic image processing in X-tension for analysis. The mandibular canal was identified by contiguous axial images

from the mandibular foramen to the inferior border of the mandible; a marker was plotted at the center of the mandibular canal in each image. To chart the course of the mandibular canal, a line was constructed by matching the markers from each image (mandibular canal line). PV images were simultaneously reconstructed in real time from multiplanar reconstruction (MPR) images of the mandibular canal line, second molar tooth crown of the same side, and alveolar crest of the same region (Figure 4). PV images of the orthogonal coronal direction and CS images were displayed at 1-mm intervals to obtain a detailed view of the relationship between the third molar root apex and the mandibular canal (Figure 5).



①: Mandibular canal running visualization line, ②: Lower third molar tooth, ③: mandibular canal

Figure 4 Making method of panoramic view images

To chart the course of the mandibular canal, a line is constructed by matching the markers from each image (mandibular canal line). PV images are simultaneously reconstructed in real time from multiplanar reconstruction (MPR) images of the mandibular canal line, second molar tooth crown of the same side, and alveolar crest of the same region.

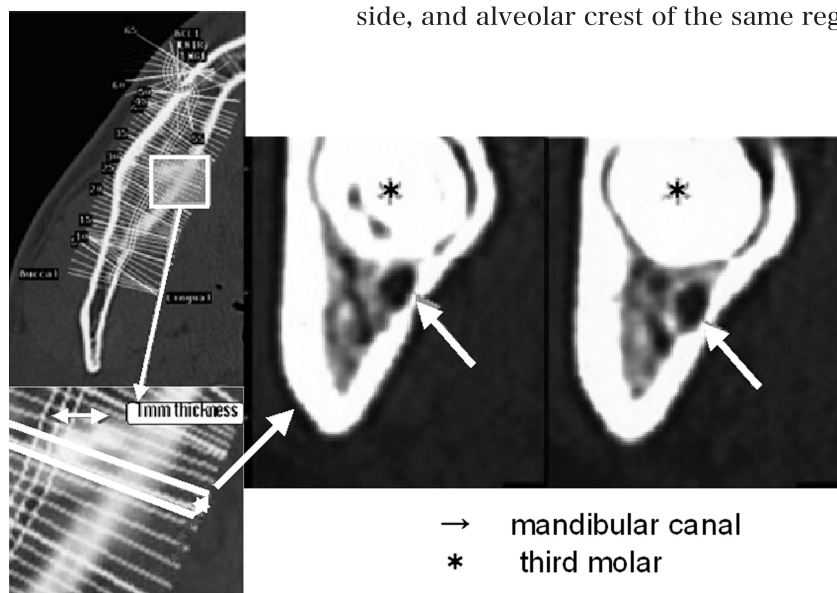


Figure 5 Cross sectional images PV images of the orthogonal coronal direction and CS images are displayed at 1-mm intervals to obtain a detailed view of the relationship between the third molar root apex and the mandibular canal.

Analyses of the positional relationship between the third molar root apex and mandibular canal, and morphology of the mandibular canal at the point of contact with the root apex

The buccolingual relationship between the third molar root apex and mandibular canal was determined by drawing the axis of the third molar on the CS image and extending a line in the direction of the root apex. The axis of the third molar was determined from repeated cine display of the CS image depicting the third molar from the crown to the root apex: the tooth axis of a single root was determined by plotting at the center of the root; the tooth axis of a curved root apex was determined by plotting at the center of the root excluding the curved area; and the tooth axis of multiple roots was determined by locating the pulpal floor and plotting at the center of each corresponding root. The mandibular canal located on the buccal side of the tooth axis extended line was defined as the buccal mandibular canal, and the mandibular canal located on the lingual side of the extended line was defined as the lingual mandibular canal. The mandibular canal located above the extended line was defined as inline mandibular canals on the tooth axis. Inline mandibular canals on the tooth axis located adjacent to the pulp chamber floor and away from the line at the apex of the tooth root bundle were defined as interradicular mandibular canals.

We observed differences in mandibular canal morphology by using CS images to compare the third molar root apex and the second molar tooth root apex. Deflection and compression of the mandibular canal was detected by cine display of CS images.

Observation of the mandibular canal bone wall

In a PV image, the mandibular canal appears as a low-density belt-shaped structure sandwiched between two parallel white lines. In a CS image, it appears as a low-density area surrounded by an oval white line. In the present study, the bone wall was detected as a continuous white line, and absence of a bone wall was determined by disruption of the white line.

Comparison of panoramic radiography and CT scans

For each case, panoramic radiographs and Tooth-Pix images of the CT scans were compared.

Analysis of buccolingual relationship

We compared Tooth-Pix images and panoramic radiographs of the buccolingual relationship between the third molar root apex and the mandibular canal. *Relationship of superimposition of the mandibular canal and third molar root apex with and without a bone wall compared between Tooth-Pix™ and panoramic radiography images*

We analyzed the relationship of superimposition of the mandibular canal and third molar root apex in the presence and absence of a bone wall on Tooth-Pix™ images and compared the results to those obtained by panoramic radiography.

Comparison between panoramic radiographic and Tooth-Pix™ findings of the third molar root apex and periapeex

We analyzed panoramic radiographs of the third molar root apex, mandibular canal morphologies, and bone wall condition and radiolucency, and Tooth-Pix images of the presence or absence of the bone wall for each case.

The panoramic radiographs and helical CT images were evaluated separately by three dentists who were certified as specialists by the Japanese Society of Oral and Maxillofacial Surgeons; these dentists had more than 10 years of clinical dentistry and oral surgery experience. Panoramic radiographs were interpreted using an x-ray film illuminator. The author recorded his own assessment of both PV and CS images, under the supervision of 2 senior oral surgeons. Observation times for panoramic radiographs and Tooth-Pix images were not specified. A determination was made when two or more dentists were in agreement. Patient names, ages, genders, and clinical information were withheld from the dentists.

Statistical analysis

Results were evaluated by χ^2 test and Fisher's exact test. $P < 0.05$ was considered significant. Post hoc analysis was performed using the Bonferroni correction.

RESULTS

Panoramic radiographic analysis

Position of the third molar root apex relative to the mandibular canal, mandibular canal deflection, and morphology and radiolucency of the third molar root apex

As shown in Table 2, panoramic radiography revealed the following positions of the mandibular canal relative to the third molar apex: Class Ia, $n = 27$ (19.1%); Class Ib, $n = 7$ (5.0%); Class IIa, $n = 68$ (48.2%); Class IIb, $n = 19$ (13.5%), Class IIIa, $n = 12$ (8.5%), Class IIIb, $n = 8$ (5.7%). Class IIa was the most frequently observed. The degree of third molar root apex depth for Class b was: Class I, 20.6%; Class II, 21.8%; and Class III, 40.0%.

Morphologic analysis of the third molar root apex revealed curvature in 12 cases (8.5%). Hyperlucency of the root was observed in 18 cases (12.8%) (Figure 6).

Table 2. Position of third molar root apex relative to the mandibular canal, as determined by panoramic radiography.

| Classification of root apex position with respect to the mandibular canal | Ia | Ib | IIa | IIb | IIIa | IIIb | Total |
|---|----|----|-----|-----|------|------|-------|
| Cases, n | 27 | 7 | 68 | 19 | 12 | 8 | 141 |

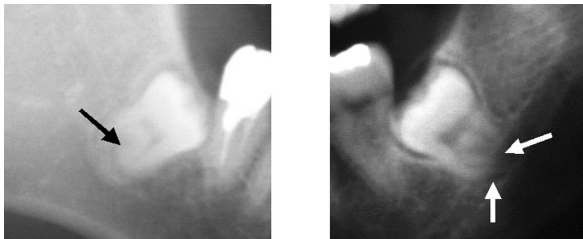


Figure 6 Curvature of root
 Mesial root have curved in the direction of the divergence part.
 Hyperlucency of tooth root
 Progression of translucency is observed at the root apex only.

Table 3. Panoramic radiography of the root apex and periapex of the mandibular canal.

| Panoramic radiographic observations | Number of cases |
|---|-----------------|
| Tooth root | |
| Hyperlucency of tooth root | 18 |
| Curvature of third molar root apex | 12 |
| Mandibular canal | |
| Loss of upper wall of the mandibular canal (white line) | 48 |
| Narrowing of mandibular canal | 4 |
| Widening of mandibular canal | 6 |
| Progression of mandibular canal translucency surrounding the root | 47 |

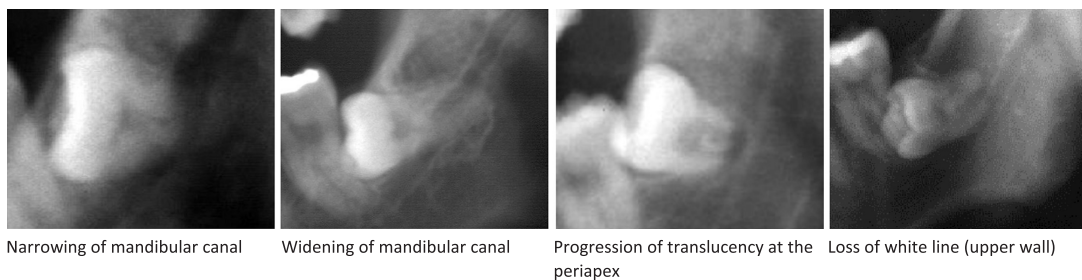


Figure 7 Narrowing of mandibular canal
 Narrowing of the translucent mandibular canal next to the central region of the third molar root is observed. A white line is not apparent at the upper and lower walls of the mandibular canal.
 Widening of mandibular canal
 Widening of the mandibular canal at the third molar root was observed. A white line is apparent at the upper and lower walls of the mandibular canal.
 Progression of translucency at the periapex
 Progression of an oval-shaped translucent image is observed at the third molar root apex surrounded by an opaque image of osteosclerosis.
 Loss of white line (upper wall)
 White line is not apparent at the point of contact between the mandibular canal and third molar root apex, thus its continuity is disrupted.

Changes in morphology and radiolucency of the mandibular canal region near the third molar root

Loss of upper mandibular canal wall near the third molar was observed in 48 cases (34.0%), but loss of the lower wall was not observed. Narrowing of the mandibular canal was observed in four cases (2.8%), and widening was observed in six cases (4.3%). With respect to changes in periapical radiolucency, mandibular canal hyperlucency at the periapex was observed in 47 cases (33.3%) (Table 3, Figure 7).

Results of Helical CT analysis

We were able to visualize the third molar and mandibular canal in all 141 cases. None of the patients had devices (e.g., metal prosthesis) that would have interfered with image analysis.

Position of third molar root apex relative to the mandibular canal, and morphology of the mandibular canal

The mandibular canal was observed on the lingual side in 34 cases (24.1%). Morphologic changes such as compression of the mandibular canal by the third molar and/or lingual cortical bone, were observed in 23 of 34 cases (67.6%).

The mandibular canal was observed on the buccal side in 49 cases (34.8%). Of these, compression of the mandibular canal by the third molar or buccal cortical bone was observed in five cases (10.2%). In-line mandibular canals on the tooth axis were observed in 58 cases (41.1%). Of these, compression of the mandibular canal by the third molar was observed in 16 cases (27.6%). Interradicular mandibular canal was observed in five cases; in one case, compression of the mandibular canal by the third molar was observed (Table 4, Figure 8).

Observations of the mandibular canal bone wall

In 49 of 141 cases (34.8%), the bone wall between the mandibular canal and third molar could not be detected on the Tooth-Pix™ images. The positions of the mandibular canal and third molar root apex were compared in cases without a bone wall. In 22 of 34

cases (64.7%), the mandibular canal was positioned on the lingual side, in 8 of 49 cases (16.3%), it was on the buccal side, and in 19 of 58 cases (32.8%), it was on the tooth axis (Table 5). Thus, a significant difference caused by absence of the bone wall was observed. The difference was greater in cases with a lingual mandibular canal than in those with a buccal mandibular canal ($p < 0.001$) or an inline mandibular canal on the tooth axis ($p = 0.0029$) (Figure 9).

Table 4. Buccolingual position of the root apex relative to the mandibular canal, as determined by CT.

| Mandibular canal position | Cases, n (compression images) |
|---|----------------------------------|
| Buccal side | 49 (5) |
| Lingual side | 34 (23) |
| Above the tooth axis (between tooth roots) | 58 (16) (5 (1)) |
| <i>Total</i> | <i>141 (44)</i> |

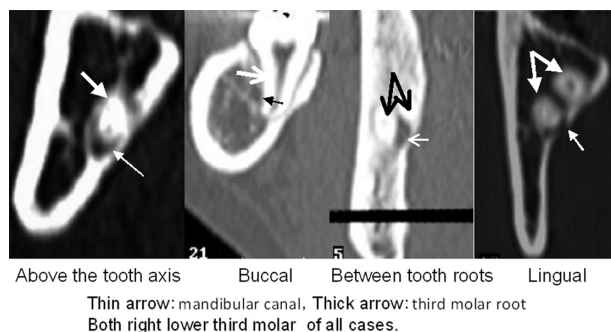
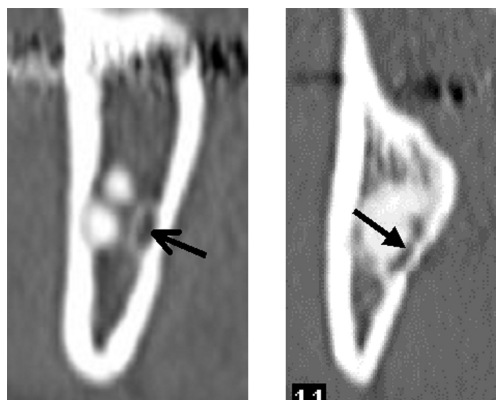


Figure 8 The buccolingual location relationship between the third molar root apex

Table 5. Buccolingual position of the mandibular canal and absence of the mandibular canal wall.

| Mandibular canal position | Cases without bone wall, n | |
|---|----------------------------|---------------------|
| | Total | Number of cases (%) |
| Buccal side | 8 /49 | 16.3 |
| Lingual side | 22/34 | (64.7) |
| Above the tooth-axis (between tooth roots) | 19/58 (4/5) | (32.8) |
| <i>Total</i> | <i>49 /141</i> | <i>(34.8)</i> |

* $p < 0.001$, ** $p = 0.0029$



Presence of bone wall Absence of bone wall
arrow: mandibular canal

Figure 9 Presence/absence of the mandibular canal bone wall at the point of contact with the third molar root apex
Presence of bone wall.

Osteosclerotic changes appear as an opaque area surrounding the translucent circular mandibular canal.
Absence of bone wall.

The translucent circular mandibular canal is not surrounded by an opaque image, and compression and resorption of the third molar root and lingual bone cortex are observed.

Comparison between panoramic radiographs and Tooth-Pix™ images

Buccolingual relationship between the third molar root apex and mandibular canal

We were able to determine the buccolingual relationship between the third molar and mandibular canal by Tooth-Pix™ software in all cases. Panoramic radiographs of cases with interradicular mandibular canals showed that all five cases were type III (Class IIIa, n = 2; Class IIIb, n = 3). However, cases in which Tooth-Pix analysis revealed other positional relationships between root apex and mandibular canal did

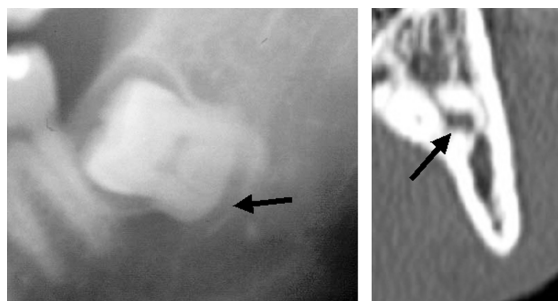
not correspond to particular panoramic radiograph results (Table 6, Figure 10).

Relationship between superimposition of the mandibular canal and third molar root apex by panoramic radiograph and the presence or absence of the mandibular canal bone wall

A bone wall was not detected by TP in 1 of the 34 Class I cases (2.9%), 34 of the 87 Class II cases (39.1%), and 14 of the 20 Class III cases (70.0%) (Table 7). Absence of bone wall was significant for Class II ($p = 0.0012$) and Class III ($p < 0.001$) cases as compared with Class I. A bone wall was absent in 25 of

Table 6. Buccolingual position of the mandibular canal relative to the third molar, and root apex depth and deflection.

| Buccolingual position | Depth of third molar root apex and deflection of mandibular canal | | | | | | | Total |
|-----------------------|---|----------|-----------|-----------|------------|------------|-----|-------|
| | Class Ia | Class Ib | Class IIa | Class IIb | Class IIIa | Class IIIb | | |
| Buccal side | 18 | 5 | 15 | 6 | 4 | 1 | 49 | |
| Lingual side | 4 | 0 | 20 | 0 | 6 | 4 | 34 | |
| Above the tooth axis | 5 | 2 | 33 | 13 | 2 | 3 | 58 | |
| (Between tooth roots) | (0) | (0) | (0) | (0) | (2) | (3) | (5) | |
| Total | 27 | 7 | 68 | 19 | 12 | 8 | 141 | |



arrow: mandibular canal

Figure 10 Panoramic radiographic and Tooth-Pix™ images of the interradicular mandibular canal

Panoramic radiographs

Translucent mandibular canal transverse the center of the third molar root apex.

Tooth-Pix™ images

Translucent mandibular canal is apparent at the center of the three roots of the third molar.

the 107 cases (23.4%) without mandibular canal deflection and 24 of 34 (70.6%) with mandibular canal deflection (Table 8). The absence of bone wall was significant in cases with mandibular canal deflection ($p < 0.001$).

Panoramic radiographs of third molar root apex and periapex, and presence or absence of bone wall in Tooth-Pix images

Bone wall was not observed by Tooth-Pix™ images in five of the 12 cases (41.7%) with curved third molar root, 13 of the 18 cases (72.2%) with root hy-

perlucency, 27 of the 48 cases (56.3%) with loss of upper mandibular canal wall, 27 of the 47 cases (57.4%) with mandibular canal hyperlucency at the periapex, four of the six cases (66.7%) with widening of the mandibular canal, and four of the four cases (100.0%) with narrowing of the mandibular canal on panoramic radiographs. Furthermore, bone wall was not observed in Tooth-Pix™ images of three of the 36 cases with no characteristic findings by panoramic radiography (Table 9, Figure 11).

Table 7. Depth of third molar root apex and presence or absence of bone wall, as determined by panoramic radiography.

| | Class I | Class II | Class III | Class Total |
|--------------------------|-----------|-----------|-----------|-------------|
| Presence of bone wall, n | 33 | 53 | 6 | 92 |
| Absence of bone wall, n | 1 | 34 | 14 | 49 |
| <i>Total</i> | <i>34</i> | <i>87</i> | <i>20</i> | <i>141</i> |

n.s., not significant; * $p=0.0012$, ** $p<0.001$

Table 8. Mandibular canal deflection, as determined by panoramic radiography, and presence or absence of bone wall, as determined by Tooth-Pix software.

| | Class a | Class b | Total |
|--------------------------|------------|-----------|------------|
| Presence of bone wall, n | 82 | 10 | 92 |
| Absence of bone wall, n | 25 | 24 | 49 |
| <i>Total</i> | <i>107</i> | <i>34</i> | <i>141</i> |

* $p<0.001$

Table 9. Panoramic radiography of tooth root and mandibular canal and absence of bone wall, as determined by Tooth-Pix™ software.

| Panoramic radiographic observations | Cases without bone wall, n (%) |
|---|--------------------------------|
| Tooth root | |
| Hyperlucency of tooth root | 13/18 (72.2) |
| Curvature of third molar root apex | 5/12 (41.7) |
| Mandibular canal | |
| Loss of upper wall of the mandibular canal (white line) | 27/48 (56.3) |
| Narrowing of mandibular canal | 4/4 (100.0) |
| Widening of mandibular canal | 4/6 (66.7) |
| Progression of mandibular canal translucency surrounding the root | 27/47 (57.4) |

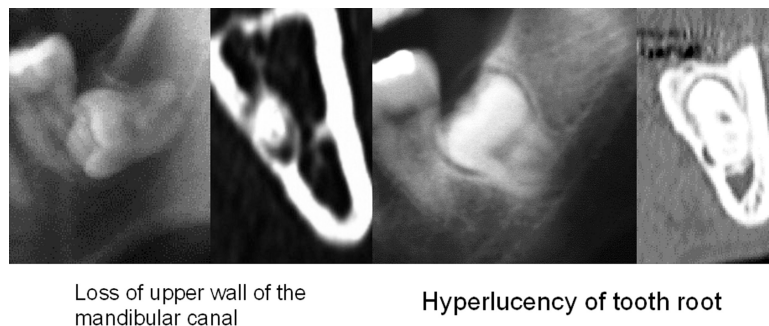


Figure 11 Panoramic radiographs of the third molar root apex and periapex in the presence and absence of a bone wall, as shown in Tooth-Pix™ images.

Panoramic radiographs

A radiolucent portion of the mandibular canal is shown horizontal to the center part of the third molar root.

Tooth-Pix™ images

A radiolucent portion of the mandibular canal can be seen in the center part of three third molar roots.

DISCUSSION

Mandibular third molar extraction is the most frequently performed surgery in the clinical practice of oral and maxillofacial surgery. The difficulty of the extraction depends on the slope of the tooth, position of impaction, and other factors. Furthermore, the inferior alveolar nerve, which enervates the lower lip and mental region, travels through the mandibular canal; therefore, it is essential to determine the three-dimensional positions of the third molar and mandibular canal before extraction of the mandibular third molar. Previous studies evaluated the combination of helical CT and panoramic radiography for visualizing the position of the mandibular canal relative to the third molar root apex [3-6]. In addition, diagnostic imaging studies of the mandibular canal have been conducted for the purpose of implant placement in recent years [7].

Panoramic radiographic imaging is the first choice for pre-surgical evaluation of a mandibular third molar extraction at our facility. When proximity of the third molar to the mandibular canal is revealed by panoramic radiograph, helical CT and image reconstruction by Tooth-Pix are performed during pre-surgical evaluation. However, helical CT cannot be performed before every third molar extraction because of concerns about radiation exposure and medical costs. In the present study, we aimed to improve the diagnostic accuracy of panoramic radiographic imaging by clarifying the extent to which panoramic radiographs can reveal the proximity of the third molar root apex to the mandibular canal.

A gold standard is needed for diagnostic imaging studies; comparison with findings during surgery is an ideal method to determine accuracy. In the present study, we investigated whether the inferior alveolar neurovascular bundle was exposed during tooth extraction. The buccolingual relationship between the mandibular canal and third molar root apex may be determined when the alveolar neurovascular bundle is exposed, but this not possible when it is not exposed. It may be possible to detect the presence of bone wall when the alveolar neurovascular bundle is not exposed; however, in cases in which the bone wall is absent, it is extremely difficult to determine whether the bone wall did not exist or an existing bone wall was destroyed during tooth extraction. In the present study, we analyzed the panoramic radiographs after scanning for the presence or absence of the mandibular canal wall with CT as the gold standard.

Panoramic radiography

Panoramic radiography is the primary imaging modality for not only third molar extraction, but also for diagnosis of periodontitis, dental caries, temporomandibular disorders, a fractured jaw, and jaw tumors [8]. Before surgical extraction of the mandibular third molar, a panoramic radiograph is taken to determine the positional relationship between the mandibular canal and third molar. During extraction, the tooth position is determined by considering impaction depth and position of the third molar crown relative to the mandibular ramus [9]. Miloro et al. [10] measured the distance between the mandibular third molar and mandibular canal in panoramic radiographs and re-

ported that mesioangular mandibular third molar impactions are the most proximal to the mandibular canal among impacted teeth. To predict the positional relationship between third molar root apex and mandibular canal, Rood et al. [11] reported the usefulness of the following seven observations: 1) darkening of the root, 2) deflected roots, 3) root narrowing, 4) dark and bifid root, 5) interruption of the white line, 6) diversion of the inferior alveolar canal, and 7) narrowing of the inferior alveolar canal. They also reported that diversion of the inferior alveolar canal, darkening of the root, and interruption of the white line were significantly associated with loss of lower lip sensation. Monaco et al. [1] reported mandibular canal in proximity to the third molar root apex in cases with increased radiolucency and narrowing and interruption of the radiopaque border, and suggested that such cases required further examination by CT.

In the present study, we categorized the positional relationship of the mandibular canal and root apex based on the degree of superimposition with the mandibular canal wall and the presence or absence of mandibular canal deflection. Furthermore, we examined the morphology and radiolucency of the third molar root apex and image findings of the mandibular canal near the third molar root apex. Results showed a higher incidence of mandibular canal deflection with an increase in overlap between the mandibular canal and third molar root apex. We observed cases with curved roots and progression of translucency in the third molar root, loss of upper mandibular canal wall, narrowing/widening of mandibular canal, and mandibular canal hyperlucency at the periapex. In the present study, we determined the extent to which panoramic radiographic findings were detected by CT scan.

Helical CT Tooth-Pix observations

Helical CT (Dental cone-beam CT) is thought to visualize the course of the mandibular canal and the number of third molar roots more accurately than panoramic radiography [12]. In the present study, we analyzed the third molar root apex and mandibular canal using reconstructed images from helical CT scans. We observed both structures in all cases. Examiners had different interpretations of the anatomical relationships between the third molar and mandibular canal, and buccolingual relationships of the mandibular canal to the third molar root apex when they examined axial images only. However, they reached the same conclusion for all cases when they examined the reconstructed image. Analysis was easier when the panoramic view and cross sectional view were examined together. Therefore, a three-dimensional image

reconstruction may be necessary when determining the anatomical relationship between mandibular canal and third molar root apex.

With regard to CT imaging of the mandibular canal, Jhamb et al. [13] reported that the mandibular canal is usually outlined by a layer of cortical bone that isolates its contents from the adjacent medulla. Furthermore, they observed indentation of the extracted tooth root by the mandibular canal, bleeding during extraction, exposure of the inferior alveolar neurovascular bundle, and numbness of the areas innervated by the inferior alveolar nerve after surgery when cortication was absent in the area of contact. Nakayama et al. [5] reported that three-dimensional CT can predict direct contact between the mandibular third molar and mandibular canal with an accuracy of 62.3% (sensitivity, 89.5%; specificity, 47.1%). This finding suggests a limit to the visualization of the mandibular canal bone wall by three-dimensional CT. However, Maegawa et al. [14] reported that a visible inferior alveolar nerve during the surgical procedure was associated with lack of cortication around the mandibular canal on CT. Conversely, exposure of the inferior alveolar neurovascular bundle after surgery was not associated with lower lip or mental paresthesia.

In the present study, we focused on the continuity of the white line of the mandibular canal bone wall. Our results showed that the bone wall was absent in 49 of 141 cases as assessed by CT.

Numerous studies have reported the association between paresthesia after third molar extraction and the buccolingual relationship between the third molar root canal and mandibular canal [13, 14]. Paresthesia is uncommon when the mandibular canal travels on the buccal side of the third molar root apex, but is more frequent when the canal travels on the lingual side under the root apex between the interradicular space. In the present study, a bone wall was absent more often in cases in which the mandibular canal traveled on the lingual side than in cases in which it traveled on the buccal side and above the tooth axis.

However, bone wall was not observed in four of five cases in which the mandibular canal traveled through the interradicular space of a multi-rooted tooth; therefore, it may be necessary to pay closer attention during the extraction of such teeth. In addition, mandibular canal compression by the third molar root apex was associated with short distances between the mandibular canal and third molar root apex. Morphologic changes, such as compression of the mandibular canal, were observed in 23 of 34 cases with mandibular canal positioned on the lingual side, which was more frequent than morphologic changes in cases with other positional relationships. Therefore, it may be neces-

sary to carefully examine morphology as well as anatomic position when analyzing the mandibular canal image.

Comparison of panoramic radiograph and Tooth-Pix images

Using simple radiography, the upper and lower walls of the retro-molar region of the mandibular canal appear as solid lines; in the molar region, the lower wall appears as a solid line, but the upper wall appears as a dotted line; and in the pre-molar region, the lower wall appears as indistinct dots but the upper wall is difficult to distinguish from the medulla [15]. It is possible to determine the position and course of the mandibular canal by panoramic radiography [8]; however, sufficient information about the buccolingual relationship between the mandibular canal and wisdom tooth, morphology of the third molar root, and continuity of the mandibular canal bone wall cannot always be obtained [14]. In the present study, panoramic radiography and Tooth-Pix images were compared to increase the accuracy of panoramic radiographic diagnosis during third molar extraction.

It is extremely important to evaluate the buccolingual relationship of the third molar root apex and mandibular canal before surgical extraction of the mandibular third molar. Conventional tomography has been used in research to examine this relationship [16]; however, helical CT is used in general because assessing this relationship using panoramic radiography is considered difficult based on its mechanism. In the present study, panoramic radiography could not differentiate root apex on the buccal side of the mandibular canal from root apex on the lingual side. However, Class III cases or cases with the root apex below the lower mandibular canal wall were associated with interradicular mandibular canal. Mandibular canal traveled on the lingual side of the third molar root in four of six cases in which widening of the mandibular canal was observed by panoramic radiography. Interradicular mandibular canal on the lingual side is associated with an exposed inferior alveolar neurovascular bundle at the site of third molar extraction [14]. Therefore, it may be necessary to pay special attention during tooth extraction when the root apex is below the mandibular canal wall, or when widening of the mandibular canal is observed on panoramic radiograph images, as the mandibular canal is likely to travel between the roots or on the lingual side.

Nakamori et al. [6] compared panoramic radiograph and CT findings, and reported that the significant difference noted was that the mandibular canal bone wall was missing in cases that demonstrated the

following four radiographic findings; distance from the inferior alveolar canal (superimposed relationship between the third molar and inferior alveolar canal), darkness of the root, diversion, and narrowing of the canal. We observed similar results in the present study; loss of continuity of mandibular canal bone wall was observed by Tooth-Pix™ in more than half of the cases with findings of narrowing/widening of the mandibular canal or mandibular canal hyperlucency at the tooth periapex. Furthermore, as compared with cases in which mandibular canal deflection was not observed at the third molar root apex area, cases with mandibular canal deflection showed a significantly higher frequency of missing bone wall on Tooth-Pix™ images.

Therefore, pre-surgical CT may be needed to determine the positional relationship when mandibular canal deflection at the root apex is detected by panoramic radiography.

During a clinical study investigating the incidence of inferior alveolar nerve injury after mandibular third molar extraction conducted by Queral-Godoy et al. [17], inferior alveolar nerve injury was observed in 1.1% of the cases, and no relationship was found between nerve injury and degree of tooth impaction. In the present study, lower lip and mental region paresthesias were not observed after surgery; however, lower lip discomfort was reported by one patient two weeks after surgery. In that case, the mandibular canal traveled on the lingual side of the third molar and bone wall was absent. Based on the results of this study, it may be difficult to determine the relationship between lower lip or chin paresthesia and the positional relationship of third molar root apex and mandibular canal. Often the bone wall cannot be observed in cases with Tooth-Pix™ findings of narrowing/widening of mandibular canal, tooth root hyperlucency, or deflection of mandibular canal at the third molar root area, making it important to pay close attention during tooth extraction in these cases.

REFERENCES

1. Monaco G, Montecvecchi M, Alessandri B, Rosaria M, Gatto A, Checchi L. Reliability of panoramic radiography in evaluating the topographic relationship between the mandibular canal and impacted third molars. *JADA* 2004;135:312-818.
2. Valmaseda-Csdellon E, Berini-Aytes L, Gary-Escoda C. Inferior alveolar nerve damage after lower third molar surgical extraction. A prospective study of 1117 surgical extractions. *Oral Surg Oral Med Oral Pathol Oral Radiol Endod* 2001;92:377-83.
3. Nakagawa Y, Ishii H, Nomura Y, Watanabe NY,

- Hoshiya D, Kobayashi K, Ishibashi K. Third molar Position: Reliability of panoramic radiography. *J Oral Maxillofac Surg* 2007;65:1303-8.
4. Susarla SM, Sidhu HK, Avery LL, Dodson TB. Does computed tomographic assessment of inferior alveolar canal cortical integrity predict nerve exposure during third molar surgery? *J Oral Maxillofac Surg* 2010;68:1296-303.
 5. Nakayama K, Nonoyama M, Takaki Y, Kagawa T, Yuasa K, Izumi K, Ozeki S, Ikebe T. Assessment of the relationship between impacted mandibular third molars and inferior alveolar nerve with dental 3-dimensional computed tomography. *J Oral Maxillofac Surg* 2009;67:2587-91.
 6. Nakamori K, Fujiwara K, Miyazaki A, Tomihara K, Tsuji M, Nakai M, Michifuri Y, Suzuki R, Komai K, Shimanishi M, Hiratsuka H. Clinical assessment of the relationship between the third molar and the inferior alveolar canal using panoramic images and computed tomography. *J Oral Maxillofac Surg* 2008;66:2308-13.
 7. Liu T, Xia B, Gu Z. Inferior alveolar canal course: a radiographic study. *Clin. Oral Impl. Res* 2009; 20:1212-8.
 8. Atchison KA. Guidelines for prescribing dental radiographs. Goaz PW, White SC. *Oral Radiology principles and interpretation.*: 3rd ed Mosby St. Louis, 1997:69-78pp.
 9. Pell GJ, Gregory GT. Impacted mandibular third molars: classification and modified technique for removal. *Dental Dig* 1933;39:330-8.
 10. Miloro M, DaBell J. Radiographic proximity of the mandibular third molar to the inferior alveolar canal. *Oral Surg Oral Med Oral Pathol Oral Radiol Endod* 2005;100:545-9.
 11. Rood JP, Nooraldeen Shehab AAA. The radiological prediction of inferior alveolar nerve injury during third molar surgery. *Br J Oral Maxillofac Surg* 1990;28:20-5.
 12. Suomalainen A, Venta I, Mattila M, Turtola L, Vehmas T, Peltola J. Reliability of CBCT and other radiographic methods in preoperative evaluation of lower third molars. *Oral Surg Oral Med Oral Pathol Oral Radiol Endod* 2010;109:276-84.
 13. Jhamb A, Dolas RS, Pandilwar PK, Mohanty S. Comparative efficacy of spiral computed tomography and orthopantomography in preoperative detection of relation of inferior alveolar neurovascular bundle to the impacted mandibular third molar. *J Oral Maxillofac Surg* 2009;67:58-66.
 14. Maegawa H, Sano K, Kitagawa Y, Ogasawara T, Miyauchi K, Sekine J, Inokuchi T. Preoperative assessment of the relationship between the mandibular third molar and the mandibular canal by axial computed tomography with coronal and sagittal reconstruction. *Oral Surg Oral Med Oral Pathol Oral Radiol Endod.* 2003;96:639-46.
 15. Starkie C, Stewart D. The intra-mandibular course of the inferior dental nerve. *J Anat.* 1931;65:319-23.
 16. Ibert DGM, Gomes ACA, Vasconcelos BCE, Silva EDO, Holanda GZ. Comparison of orthopantomographs and conventional tomography images for assessing the relationship between impacted lower third molars and the mandibular canal. *J Oral Maxillofac Surg.* 2006;64:1030-7.
 17. Godoy EQ, Castellon VC, Aytes LB, Escoda CG. Incidence and evolution of inferior alveolar nerve lesion following lower third molar extraction. *Oral Surg Oral Med Oral Pathol Oral Radiol Endod* 2005; 99:259-64.

Received October 22, 2010

Accepted November 19, 2010